

# First Report of Pre-operative Detection of Two *TERT* Promoter Mutations Within a Papillary Thyroid Carcinoma

Harari, Amir;<sup>1</sup> Huiras, Jennifer;<sup>2</sup> Chen, Yang;<sup>2</sup> Alshalalfa, Mohammed;<sup>2</sup> Hao, Yangyang;<sup>2</sup> Klopper, Joshua P.;<sup>2</sup> Kloos, Richard T.;<sup>2</sup> Vazquez, Bianca J.<sup>3</sup>

1. Endocrinology Associates, Scottsdale, AZ. 2. Veracyte, South San Francisco, CA. 3. Arizona Thyroid & Parathyroid Surgery, Scottsdale, AZ.



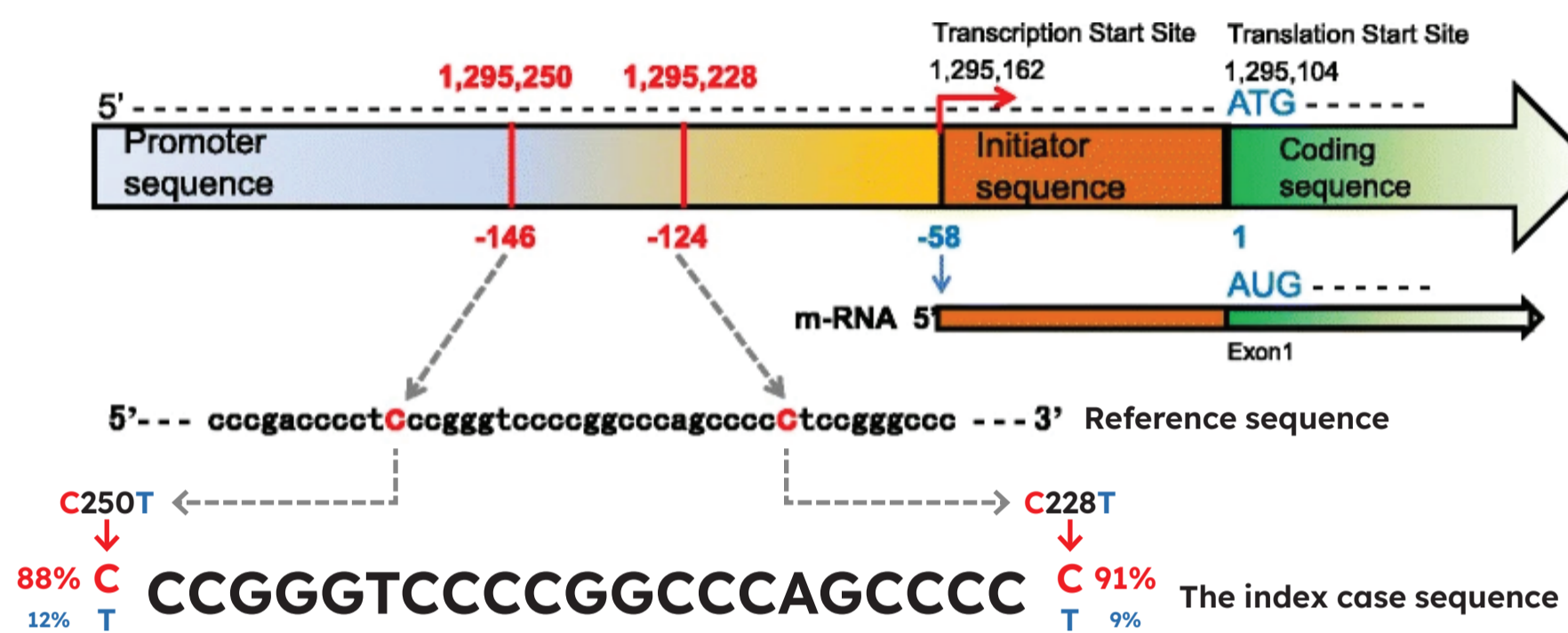
## INTRODUCTION

- Telomeres are condensed DNA-protein structures on the ends of chromosomes. Over the life of a cell, telomeres shorten with cell division, leading to DNA damage and decreased cellular proliferation. Telomerase activation, which can occur with telomerase reverse transcriptase promoter (*TERT*) mutations, is a phenomenon cancer cells use to maintain telomere length and induce cell immortality (figure 1).<sup>1</sup>
- TERT* promoter mutations are associated with aggressive thyroid cancer and are most prevalent in anaplastic and poorly differentiated thyroid cancer.
- Pre-operative thyroid nodule molecular testing can detect *TERT*, denoting a high risk of malignancy and possible aggressive clinical features such as extrathyroidal extension and regional (if not distant) metastases.
- There are two described hot spot point mutations: the more common C228T and the less common C250T variant. Canonically, these mutations are mutually exclusive and drive monoallelic *TERT* expression. In this report, we describe a case of both the C228T and C250T variants being detected in the same thyroid cancer.

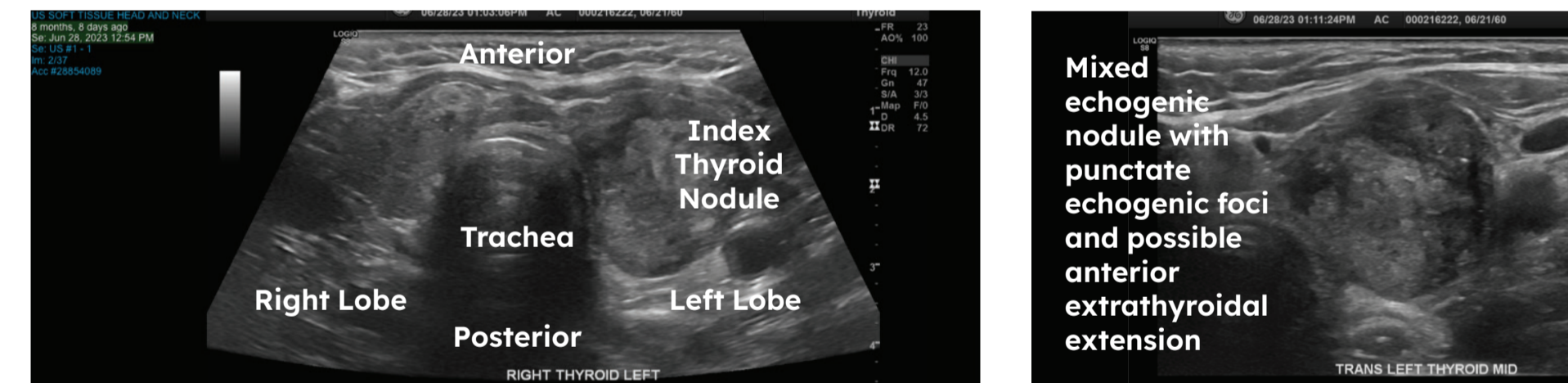
## CASE DESCRIPTION

- A 62-year-old female presented with neck discomfort and left anterior swelling.
- She had a TSH of 2.43 (ref 0.45-4.5 uIU/mL), TPO abs of 326 (ref 0-34 IU/mL) and Tg abs of 1.8 (ref 0-0.9 IU/mL).
- Neck ultrasound reported a 2.3 cm mixed iso and hypoechoic nodule with possible microcalcifications (TR4 by ACR-TIRADs) (figure 2).
- Fine needle aspiration biopsy resulted in Bethesda VI cytology, consistent with papillary thyroid cancer (PTC).
- The sample was sent for Afirma Genomic Sequencing Classifier (GSC) and *TERT* promoter mutation molecular testing and was found to have a BRAFV600E mutation along with *TERT* mutations at the C228T and C250T locations on different alleles (figures 1 and 3).
- Given the novelty of the dual *TERT* mutation and to verify there was not contamination from another sample, kinship (relatedness between individuals) analysis<sup>3</sup> was performed as a quality control test in the Veracyte lab and confirmed the result was from the same patient (figure 4).
- The patient provided consent to have this case reported and clinical data was collected under WCG IRB protocol DHF 005-077.
- Histopathology of a total thyroidectomy with central lymph node dissection showed a 4.0 cm classic PTC with clinical invasion into the strap muscle, lymphatic invasion, and a focally positive anterior surgical margin. Five of 24 lymph nodes were positive with no extra-nodal extension noted. The final pathological stage was pT3bN1aMx (stage II disease by AJCC 8th edition).
- Approximately 6 weeks postoperatively the patient had a TSH of 0.29 uIU, thyroglobulin level of <0.1 ng/mL and anti-thyroglobulin antibodies of 3 (ref 0.9-3.9 IU/mL).
- The patient was treated with 75 mCi of <sup>131</sup>I and the post-therapy RAI scan only showed neck uptake and a 3-month post-treatment thyroglobulin remained undetectable with anti-thyroglobulin antibodies in the reference range. A neck US is pending.

**FIGURE 1.** Genomic position and sequence of *TERT* promoter mutations reported in thyroid cancer<sup>2</sup> and the detected variants with the allelic frequency in the current case



**FIGURE 2.** Representative thyroid US images of the index lesion



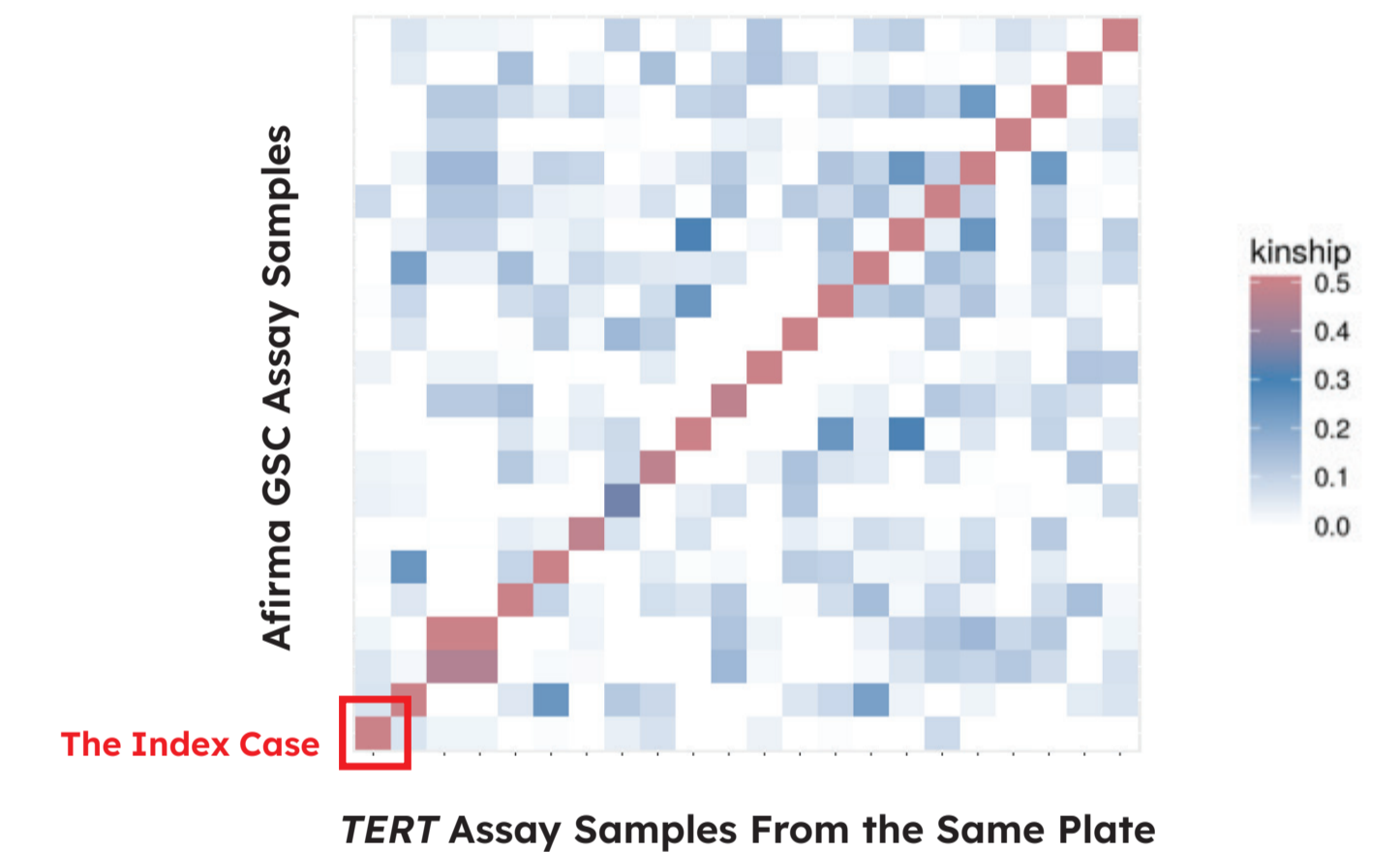
**FIGURE 3.** The Afirma GSC and *TERT* promoter region results report indicating the presence of a BRAFV600E mutation along with the two detected *TERT* promoter mutations

| AFIRMA GENOMIC SEQUENCING CLASSIFIER                |                       |   |   |
|---|-----------------------|---|---|
| Ensemble Classifier                                 | Xpression Atlas       | Other Classifiers   |   |
| N/A   | BRAFp:V600E c.1799T>A | BRAF p. V600E c. 1799T>A: Positive<br>RET/PTC1, RET/PTC3: Not Detected                        | MTC: Negative<br>Parathyroid: Negative  |
| Clinical Relevance                                  | Risk of Malignancy    | Associated Neoplasm Type  | FDA Approved Therapy <sup>4</sup>   |
| Evidence of clinical significance in thyroid cancer | >95% <sup>11</sup>    | PTC   | In unresectable or metastatic thyroid cancer that has progressed following prior treatment. See Medication prescribing information for appropriate patient selection. |
| TERT PROMOTER REGION                                |                       |   |   |
| TERT c.-124C>T (C228T): Positive                    |                       | TERT c.-146C>T (C250T): Positive  |   |
| Clinical Relevance                                  | Risk of Malignancy    | Associated Neoplasm Type  | FDA Approved Therapy <sup>4</sup>   |
| Evidence of clinical significance in thyroid cancer | >95% <sup>8</sup>     | Differentiated Thyroid Carcinoma (PTC, FTC, FVPTC) or poorly differentiated thyroid carcinoma | In unresectable or metastatic thyroid cancer that has progressed following prior treatment. See Medication prescribing information for appropriate patient selection. |

**FIGURE 4.** Kinship analysis of all *TERT* samples run during the index case analysis

Patient samples are matched on the X and Y axis in the same order (identifiers deleted). Kinship score between Afirma GSC-*TERT* samples are calculated based on common 40 single nucleotide polymorphisms (SNPs) that are detected by both RNA and DNA assays. Samples from the same patient have very similar SNP profiles and have high kinship scores (~0.5). The larger block indicates two nodules assessed from the same patient.

**Kinship Between *TERT* - Afirma Sample Pairs**



## DISCUSSION

- The Afirma *TERT* promoter mutation assay is assessed on Afirma GSC-suspicious samples and those with Bethesda V and VI cytology. The analytical validation demonstrating the accuracy and consistency of the assay was recently reported.<sup>4</sup>
- To our knowledge, this is the first report of dual *TERT* mutations in a thyroid carcinoma and the first reported in pre-operative testing.
- This phenomenon has been reported in glioma, melanoma, and bladder cancer.
- Given the potential of transcriptional compensation, it is unknown if monoallelic dual *TERT* promoter mutations would be less activating of overall telomerase activity than would biallelic mutations as found here. Clinical correlation with future cases will be of interest.

## References

- Yuan et al. *Clin Transl Med*. 2022 Nov;12(11):e1111. doi: 10.1002/ctm2.1111.
- Bae et al. *Diagn Pathol*. 2016 Feb 9;11:21. doi: 10.1186/s13000-016-0458-6.
- Choi et al. *Model Assisted Statistics and Applications*. 2017 Jan 1; 265 - 273.
- Iyer et al. *J Clin Endocrinol Metab*. 2024 Mar 5;dgae134. doi: 10.1210/clinem/dgae134.